TBL – 1
NEU Block

Q1: Which of the following properties belong to an electrical synapse?

A. Electrical to chemical to electrical mode of synaptic neurotransmission
B. The membranes of the two neurons are separated by a large gap
C. Current can only propagate in a unidirectional way
D. Enables transfer of ionic current directly to the next neuron
E. Electrical synapses have asymmetrical morphology

Ans: D

Q2: Several structures in the brain lack blood brain barrier. Which of the following structures is sensitive to changes in plasma sodium concentration?

A. The pineal gland
B. The neurohypophysis
C. The subfornical organ
D. The median eminence
E. The area postrema

Ans: C

Q3: Which of the following statements concerning the resting membrane potential is correct?

A. A membrane is depolarized when the separation of the charge across the membrane is increased
B. As the inside of the cell is made more negative with respect to the outside, the cell becomes depolarized
C. In a cell whose membrane possesses only potassium channels, the membrane potential cannot be determined
D. The resting membrane potential is unrelated to the separation of the charge across the membrane
E. Passive fluxes of sodium and potassium are balanced by an active pump that derives energy from enzymatic hydrolysis of adenosine 5'- triphosphate

Ans: E

Q4: A 56 year old woman reports to the ER complaining of severe muscle weakness, tingling sensation, and numbness. Serum analysis on admission reveals a K+ concentration of 6.7 mEq/L [3.5 - 5 mEq/L]. Which of the choices below is the cause of hyperkalemia induced symptoms in this patient?

A. The resting membrane potential is hyperpolarized
B. The potassium equilibrium potential is more negative
C. Na+ channels are inactivated
D. The sodium equilibrium potential is more negative
E. Na+ channels are closed during repolarization

Ans: C

Q5: Which of the following is seen in anterior cord syndrome?

A. Loss of proprioception
B. Loss of two-point discrimination
C. Loss of pain sensation
D. Astereognosis
E. Loss of vibration sensation

And: C

Q6: you are shown an MRI study with pre- contrast (T1) weighted image of lumbar spine. Which of the following is the likely diagnosis?

A. Osteomyelitis
B. Schmorls nodes
C. Hemingioma
D. Chance fracture
E. Multiple myeloma

Ans: E

Q7: Which of the following neurotransmitters do not have ionotropic receptors?

A. GABA
B. Glutamate
C. Acetylcholine
D. Dopamine
E. Serotonin

Ans: D

Q8: 23-year-old Zafar received multiple gunshot injuries in the back while resisting an attempted robbery. At the local hospital after initial resuscitation, a myelography was carried out which involves injection of a radio-opaque dyein subarachnoid space and subsequent imaging by X-ray. This was done to assess the extent of damage to his spinal cord since MRI facility was not available. An MRI done the next day showed hemi-section of the spinal cord at the level of the left T8 vertebra. 3 weeks later, the neurological exam of his lower limbs showed unilateral stiffness with brisk deep tendon reflexes, and positive Babinski sign. With the above mentioned lesion, where will Zafar be expected to have loss of pain and temperature?

A. Right lower limb
B. Both lower limbs
C. Both groin regions
D. Left groin region
E. Left lower limb

Ans: A

Q9: A 30-year-old presented to the neurological clinic with tingling and loss of vibrations and touch sensation in both lower limbs. On neurological examination he has spastic type of paralysis in both lower limb with babinski's sign positive in both feets. In his past surgical history he has part of his stomach removed in bariatric surgery 5 years ago. He is also suffering from pernicious anemia. In an MRI scan which spinal cord tract would show demyelination?

A. anterior spinocerebellar tract
B. Lateral corticospinal tract
C. Posterior spinocerebellar tract
D. Anterior spinothalamic tract
E. Anterior corticospinal tract

Ans: B

Q10: Morphine is contraindicated in which one of the following pain conditions?

A. Cancer pain
B. Biliary colic
C. Bone fracture
D. Intestinal fracture
E. Myocardial infarction

Ans: B

Q11: A patient after a stroke presented with loss of pain and temperature over the right side of the face. Which one of the following nuclei is responsible for this presentation?

A. Nucleus ambiguus
B. Nucleus Solitarius
C. Substantia gelatinosa
D. Nucleus gracilis
E. Spinal trigeminal nucleus

Ans: E

Q12: A patient after a stroke presented with difficulty of swallowing. Which one of the following nuclei is responsible for this presentation?

A. Nucleus ambiguus
B. Nucleus tractus solitarius
C. Hypoglossal nucleus
D. Nucleus gracilis
E. Nucleus cuneatus

Ans: A

Q13. A junior resident in medicine rapidly treated hyponatremia in a patient. A few days later the patient developed quadriplegia. The brain MRI would show demyelination of which part of the brain?

A. Pyramids of medulla
B. Crus cerebri of midbrain
C. Posterior limb of internal capsule
D. Tegmentum of pons
E. Basilar part of pons

Ans: E

Q14: A woman presented to the ER with ptosis of the right eye lid, lateral strabismus, and spastic paralysis of the left side of the body. The woman most probably has a lesion in:

A. Right midbrain
B. Left midbrain
C. Right pons
D. Left pons
E. Right medulla

Ans: A

Q15: Which part of the spinal nerve contains only efferent fibers?

A. Dorsal root
B. Dorsal Ramus
C. Ventral Ramus
D. Ventral root
E. Plexus

Ans: D

Q16: A carpenter suffers a bad fall that results in head trauma. His motor, sensory, and language skills are intact after the incident, and he has no visual problem. In the following weeks, he begins to lose interest in his work and doesn't seem to care much about his family. Which part of the cerebrum was most likely affected?

A. Frontal Lobe
B. Temporal Lobe
C. Parietal Lobe
D. Occipital Lobe

Ans: A

Q17: A 26-year-old woman who is fond of wearing high-heeled shoes, noted marked pain in the left foot for the past 3 months. On physical examination, she has severe pain on palpation of the interdigital space between the second and third toes. There is no visual swelling or erythema of the foot. Motor strength in the lower extremities seems to be normal. What kind of neuropathy is she suffering from?

A. Hereditary
B. Vasculitic
C. Compression
D. Metabolic
E. Infectious

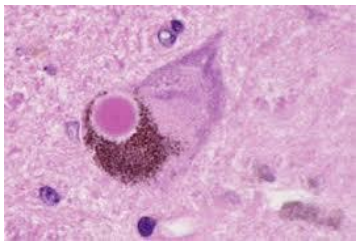

Ans: C

Q18: A 78-year-old male suffering from a chronic neurodegenerative disease died of aspiration pneumonia.H&E stained section from his autopsied midbrain is shown in the attached figure. Which one of the following characteristic change related to his neurodegenerative disorder is seen in the figure?

A. Lafora body
B. Neurofibrillary tangle
C. Lewy body
D. Cowdry body
E. Negri body

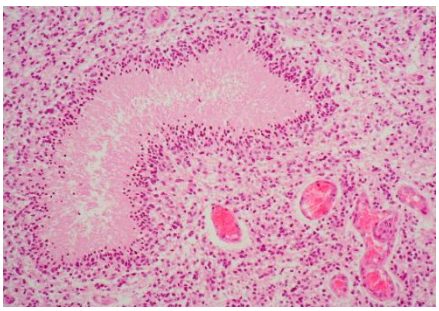

Ans: C

Q19: A 50-year-old woman presented with 3 month history of headaches is brought to the emergency department following a generalized tonic-clonic seizure. On physical examination, she has weakness on the right side. An MRI of her brain shows a large, irregular, 8-cm mass in the right cerebral hemisphere that extends across the corpus callosum. A stereotactic biopsy of the mass is done and histological findings are shown in the figure. Which of the following neoplasms is she most likely to have?

A. Pilocytic astrocytoma
B. Ependymoma
C. Meningioma
D. Glioblastoma multiforme
E. Medulloblastoma

Ans: D

Q20: A 29-year-old lady with a space occupying lesion in the brain, presented with inability to produce speech. Which is the most likely affected area?

A. Primary motor cortex
B. Wernicke area
C. Arcuate fasciculus
D. Broca's area
E. Nucleus ambiguous

Ans: D

Collected by:
10th Batch Exam Committee
Good Luck :)